Children's Environmental Health and Neuroimaging

An Introduction to the Field

Kim M. Cecil, PhD

Professor of Radiology, Pediatrics, Neuroscience and Environmental Health

Cincinnati Children's
changing the outcome together

University of CINCINNATI

Objectives

- Introduce Imaging Modalities
- Illustrate Neurodevelopment with Magnetic Resonance Imaging (MRI)
- Introduce Advanced MRI Techniques
- Examples with Imaging of Environmental Exposures

Brain Composition

The brain is mostly water

- Content 92-95% in neonate, 82-85% in adult

- Gray Matter
  - Neuronal cell bodies, glia, and capillaries
- White Matter
  - Axons, myelin, oligodendrocytes
- Cerebrospinal Fluid (CSF)
  - Water like substance that cushions the brain and also transports hormones and waste products

Brain Pathology and Injury

- Visually Detectable by Imaging
  - Abnormal size, shape, composition, contrast
    - Absence of a structure
    - Malformation of a structure, a tissue
    - Destruction of a structure, tissue
      - Volume Loss, Degeneration, Demyelination
    - Addition of a structure
      - Cyst, Hemorrhage, Neoplasm
- Microscopic Level Becoming Quantifiable by Imaging
  - Abnormal functional development
    - Abnormal neurotransmission, circuitry, networks

Available Techniques

- Ionizing Radiation
  - X-Ray
  - Computed Tomography (CT or CAT)
  - Nuclear Medicine
    - Positron Emission Tomography (PET)
    - Single Photon Emission Computerized Tomography (SPECT)

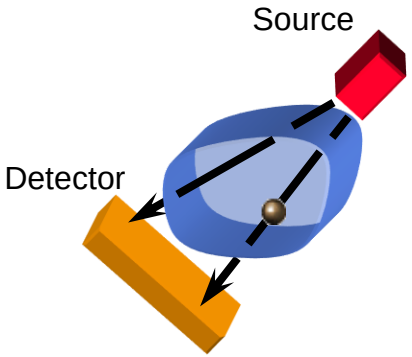

Concerns

Without a clinical indication,

- Limited pediatric studies for research purposes
- Limited longitudinal analyses for research purposes

Available Techniques

Ultrasound operates at sound wave frequencies from 20 kHz to 2 MHz.

Benefits

- Ultrasound reflects tissue reflectivity and velocity
- Ease of implementation, portable
- Relatively inexpensive

Concerns

- Limited signal penetration
- Limited spatial coverage

Magnetic Resonance Imaging (MRI)

Concerns for MRI Usage

- While there are no biohazards, safety can be an issue
- Contraindications
- Motion
- Sedation
  - Infants and children
  - Adults with claustrophobia for MRI
- Expensive
  - Staffing, Device
- Fixed Location

Intrinsic Parameters: MRI

- Nuclear Spin Density: Hydrogen (water, fat) concentration
- Motion on the Molecular Scale: T1, T2 relaxion
- Motion on the Microscopic Scale: Diffusion, Perfusion
- Macroscopic Motion: Velocity, Flow, Acceleration, etc.
- Chemical Composition
- Chemical Exchange
- Temperature
- Mechanical Properties of Tissue

Brain Development - Visualized

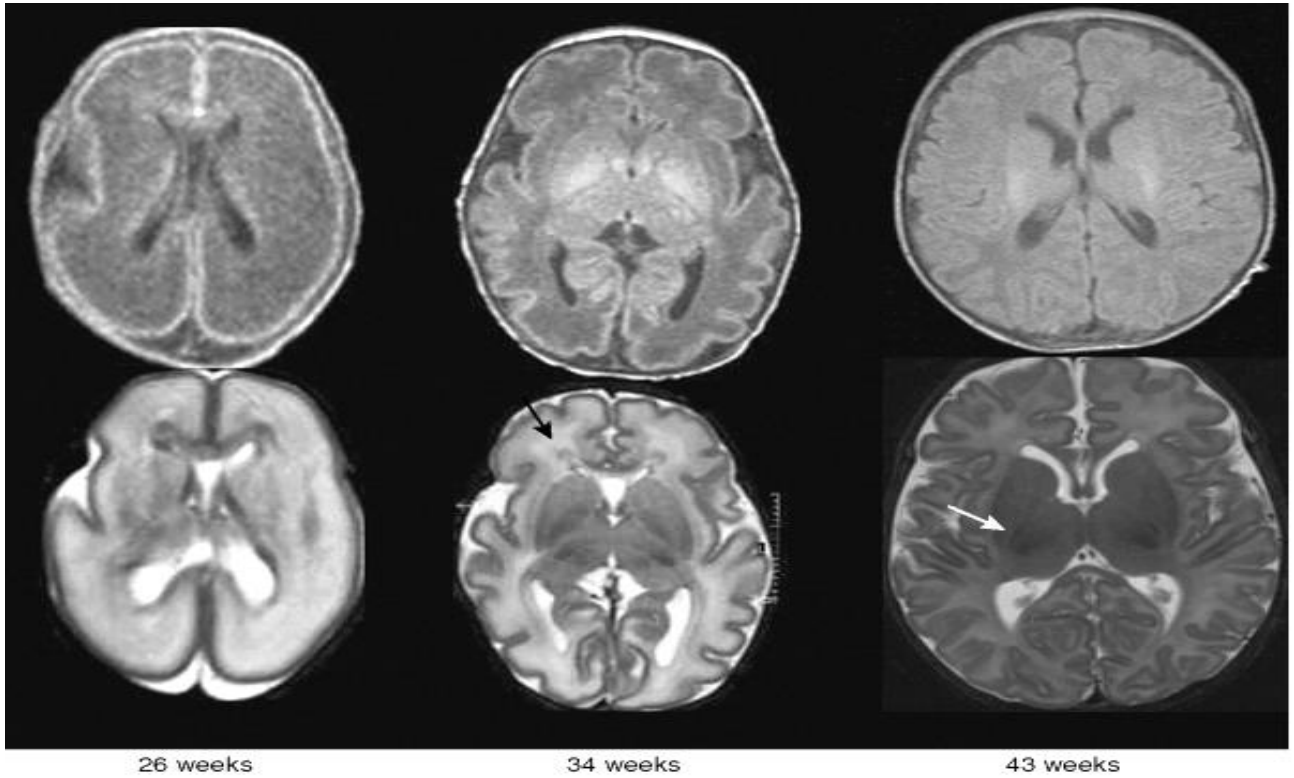

Pediatric Radiology 2006, 36, 593-607

Brain Development - Visualized

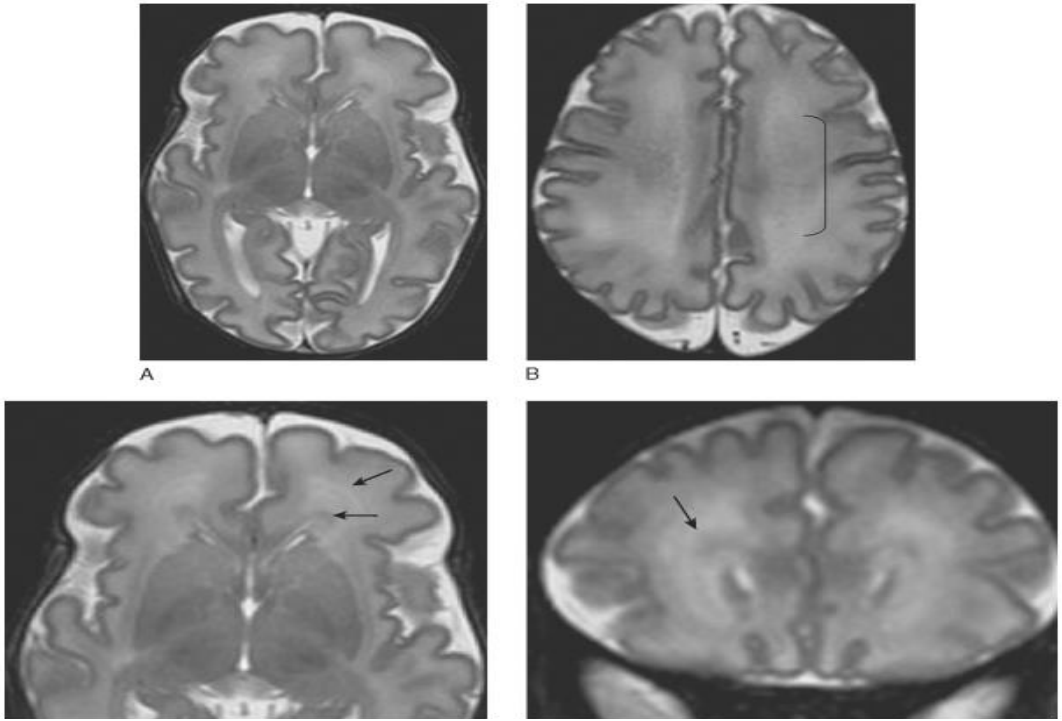

FIGURE 31-12 MRI shows cellular migration in a neonate of 33 weeks' gestational age. **A** and **B,** Images through **A,** the lateral ventricles, and **B,** the centrum semiovale. **C,** Magnified view of **A.** **D,** Magnified coronal view. **A, C,** and **D,** Low-intensity bands of migrating glial cells seen in the deep frontal periventricular white matter *(arrows)*. **B,** Corresponding "stripes" due to migrating glial cells are seen in the centrum semiovale *(bracket)*.
(From Arthur R: Magnetic resonance imaging in preterm infants. Pediatr Radiol 2006;36:593-607.)

TABLE 47-3 -- Myelination Timetable on T2-Weighted Spin Echo Conventional and Fast Spin Echo

Brain Structure	Myelination	
POSTERIOR FOSSA		
Brainstem	Birth	Mature by 6 mo
Cerebellar peduncles		
Superior and inferior	Birth	Mature by 6 mo
Middle	2-3 mo	Mature by 6 mo
Cerebellar hemisphere		
Deep inferior portion	1 mo	Mature by 18 mo
Central portion	3 mo	Mature by 18 mo
Peripheral extension into folia	8 mo	Mature by 18 mo
DIENCEPHALON		
Thalamus (medial-dorsal)	Birth	
SUPRATENTORIUM		
Optic		
Radiation	2 mo	
Tract	1 mo	
Internal capsule		
Posterior limb	Birth	
Anterior limb	4 mo	
All parts	8-12 mo	
Corpus callosum		
Splenium	4 mo	
Genu	8 mo	
All parts	12 mo	
Postcentral gyrus	Birth	
Calcarine gyrus	3 mo	
Precentral gyrus	2-3 wk	
Centrum semiovale (central)	Birth–2 mo	
Cingulum	2 mo	
LOBES OF BRAIN		
Calcarine cortex	Mature by 6.5-15 mo	
Heschl gyrus	Mature by 6.5-15 mo	
Postcentral gyrus	Mature by 6.5-15 mo	
Precentral gyrus	Mature by 6.5-15 mo	
Posterior frontal	Mature by 6.5-15 mo	
Posterior parietal	Mature by 6.5-15 mo	
Occipital pole	Mature by 6.5-15 mo	
SUBCORTICAL WHITE MATTER ASSOCIATION: FIBERS OF		
Temporal lobe	Mature by 21-26.5 mo	
Temporal pole	Mature by 21-26.5 mo	
Frontal pole	Mature by 21-26.5 mo	

Data from Byrd SE, Darling CF, Wilczynski MA: White matter of the brain. Neuroimaging Clin N Am 1993;3:247-266.

Children's Health | Article

Prenatal PCB Exposure, the Corpus Callosum, and Response Inhibition

Paul Stewart,[1] Susan Fitzgerald,[1] Jacqueline Reihman,[1] Brooks Gump,[1] Edward Lonky,[1] Thomas Darvill,[1] Jim Pagano,[2] and Peter Hauser[3]

[1]Psychology Department and [2]Environmental Research Center, State University of New York at Oswego, Oswego, New York, USA; [3]Neurosciences Division, Portland Veterans Administration Medical Center, Portland, Oregon, USA

The present study reports the association between prenatal exposure to polychlorinated biphenyls (PCBs), the corpus callosum, and response inhibition in children who are 4.5 years old. Children (n = 189) enrolled in the Oswego study were tested using a continuous performance test. We measured (square millimeters) the splenium of the corpus callosum, a pathway implicated in the regulation of response inhibition, using magnetic resonance imaging. Results indicated a dose-dependent association between cord blood PCBs and errors of commission. Splenium size but not other brain areas predicted errors of commission (r^2 = 0.20), with smaller size associated with more errors of commission. There was an interaction between splenium size and PCB exposure. The smaller the splenium, the larger the association between PCBs and errors of commission. If the association between PCBs and response inhibition is indeed causal, then children with suboptimal development of the splenium are particularly vulnerable to these effects. These data await replication. *Key words:* corpus callosum, impulsivity, inhibition, PCBs, polychlorinated biphenyls, splenium. *Environ Health Perspect* 111:1670–1677 (2003). doi:10.1289/ehp.6173 available via *http://dx.doi.org/* [Online 16 June 2003]

Mapping callosal morphology and cognitive correlates

Effects of heavy prenatal alcohol exposure

E.R. Sowell, PhD; S.N. Mattson, PhD; P.M. Thompson, PhD; T.L. Jernigan, PhD; E.P. Riley, PhD; and A.W. Toga, PhD

Article abstract—*Background:* Abnormalities of the corpus callosum (CC) have been documented in fetal alcohol syndrome (FAS), ranging from subtle decrements in its size to partial and even complete agenesis. Prenatal exposure to alcohol is also known to result in neurocognitive deficits. *Objective:* To 1) investigate abnormalities in size, shape, and location of the CC within the brain in individuals with FAS and in those exposed to high amounts of alcohol prenatally but without FAS (PEA group); and 2) determine if there is a relationship between callosal dysmorphology and cognitive test performance. *Methods:* MRI and novel surface-based image analytic methods were used. Twenty alcohol-exposed subjects (8 to 22 years) along with 21 normal controls (8 to 25 years) were studied with high-resolution MRI and measures of verbal learning and visuospatial abilities. *Results:* In addition to callosal area reductions, most severe in the splenium, the CC is significantly displaced in patients exposed to alcohol prenatally. In the alcohol-exposed group, this structure lies more anterior and inferior in posterior regions with relatively normal localization of anterior regions. These findings are significant in the FAS group, and a similar but less severe pattern is observed in the PEA patients. The authors show that the amount of CC displacement is correlated with impairment in verbal learning ability and that CC displacement is a better predictor of verbal learning than regional CC area. The brain–behavior relationship is only significant within the alcohol-exposed group, and the effect is not solely mediated by overall impaired verbal intellectual functioning. *Conclusions:* These results further emphasize the vulnerability of midline brain structures to prenatal alcohol exposure.

NEUROLOGY 2001;57:235–244

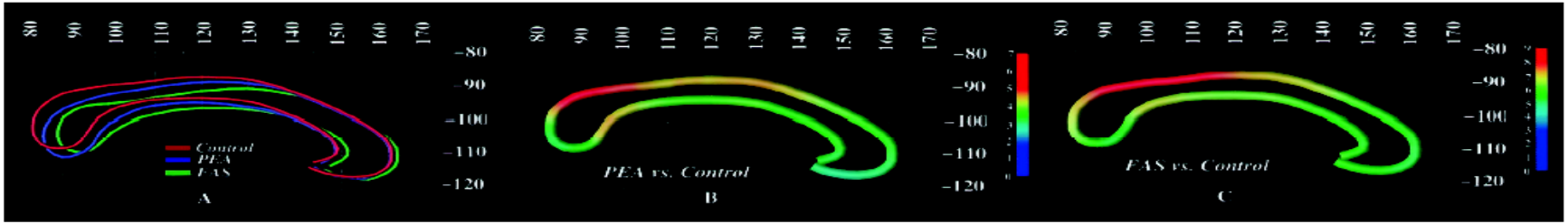

Figure 3. (A) Average callosal lines in ICBM-305 standard space shows the distinctions between fetal alcohol syndrome (FAS), prenatal exposure to alcohol (PEA), and control subjects. Note the placement of the corpus callosum in PEA subjects somewhere between that of the control and FAS subjects, but with a similar pattern of displacement. (B) Map (in ICBM-305 space) shows average displacement vectors in millimeters between the PEA and control subjects, and (C) between FAS and control subjects. Again, the pattern of displacement is the same in the PEA subjects, but the displacement is somewhat less severe than that observed for the FAS subjects.

Advanced Magnetic Resonance

- Volumetric and Surface Features
  - High resolution anatomical Imaging
    - Microscopic volume
    - Cortical thickness measures
  - Specialized software
- Perfusion
  - Endogenous contrast mechanism (Arterial Spin Labeling)
  - Reveal blood flow, distribution and volume

Advanced Magnetic Resonance

- Functional Imaging of the Brain
  - Perform a cognitive or motor task, detect localized paramagnetic changes from blood with rapid imaging
  - Can also be performed as “resting state” without a task
  - Reveal neuronal function associated with a given task
- Diffusion Imaging of the Brain
  - Track the diffusion of water along fiber pathways using rapid imaging and strong gradients
  - Reveal white matter tract organization in the brain
- Spectroscopy of the Brain
  - Measure proton signals of amino acids in selected regions by suppressing water signals
  - Discern pathology based upon the chemical profile

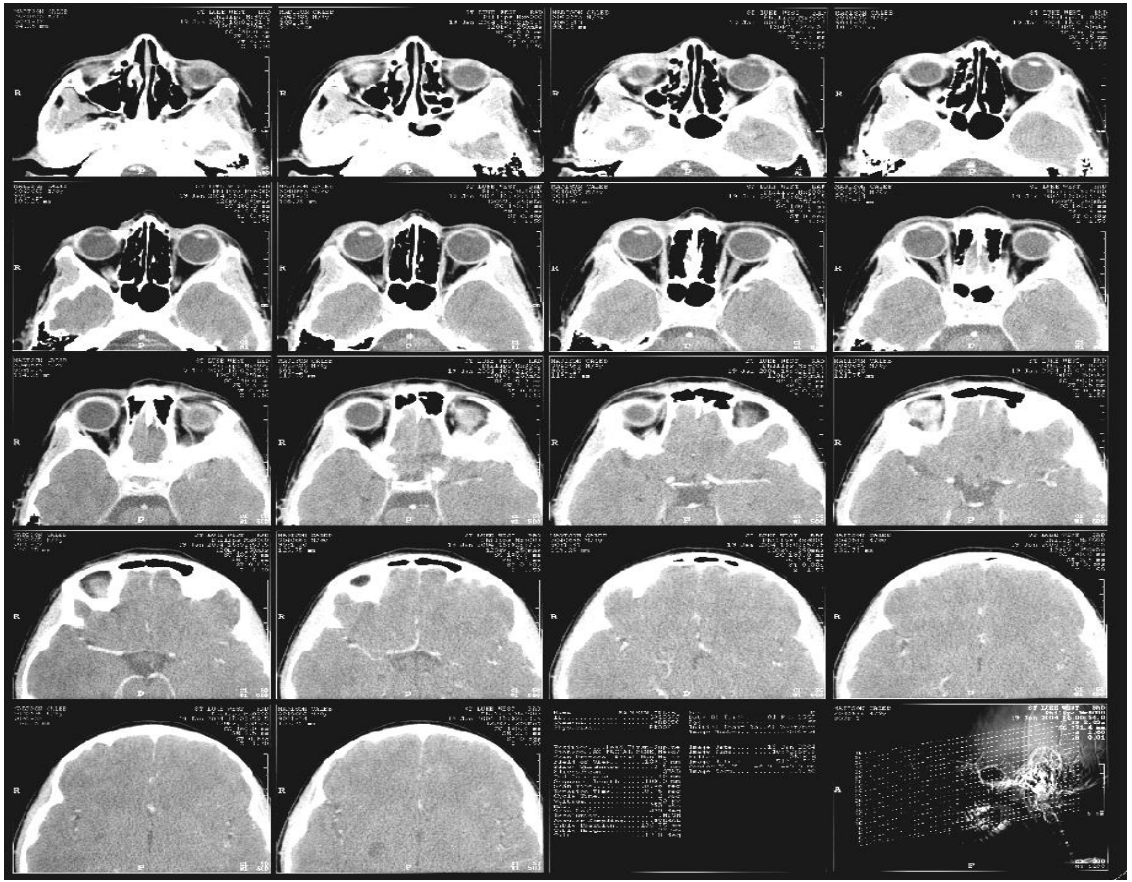

Orbital Computerized Tomography (CT)

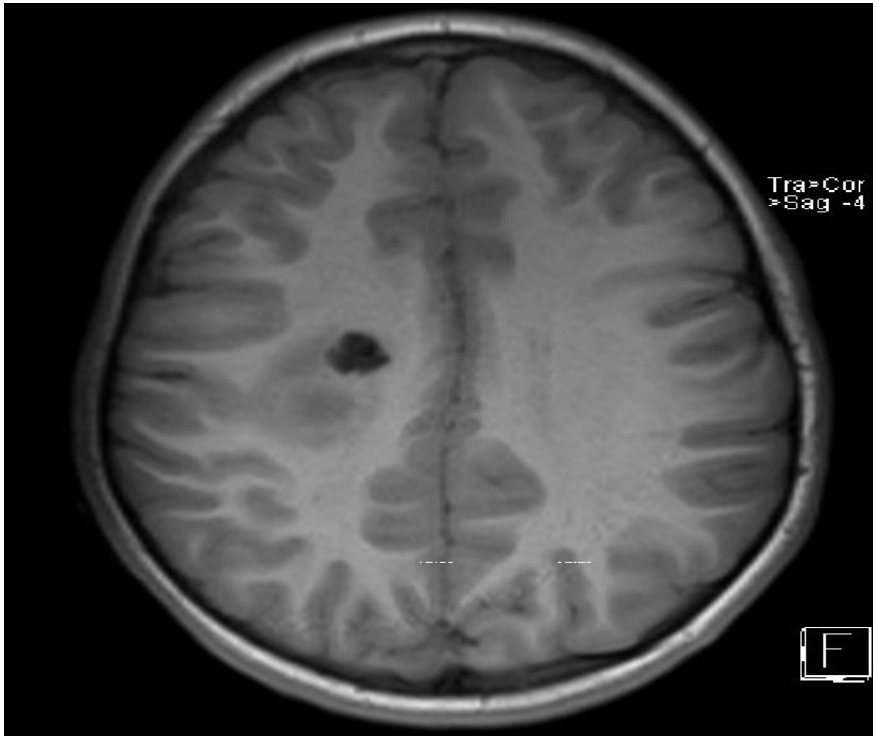

High Field (3 Tesla) T1 weighted

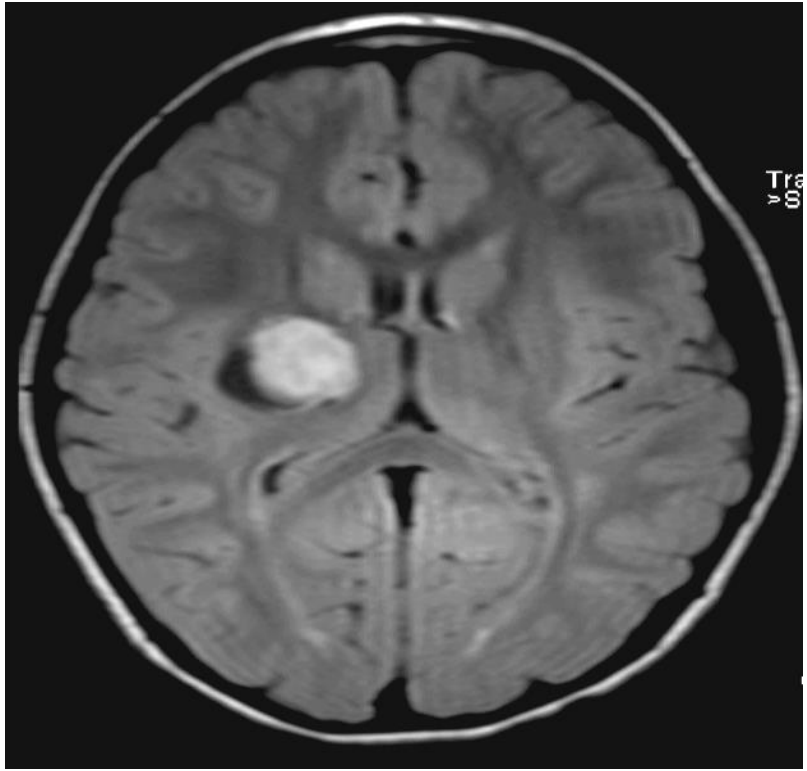

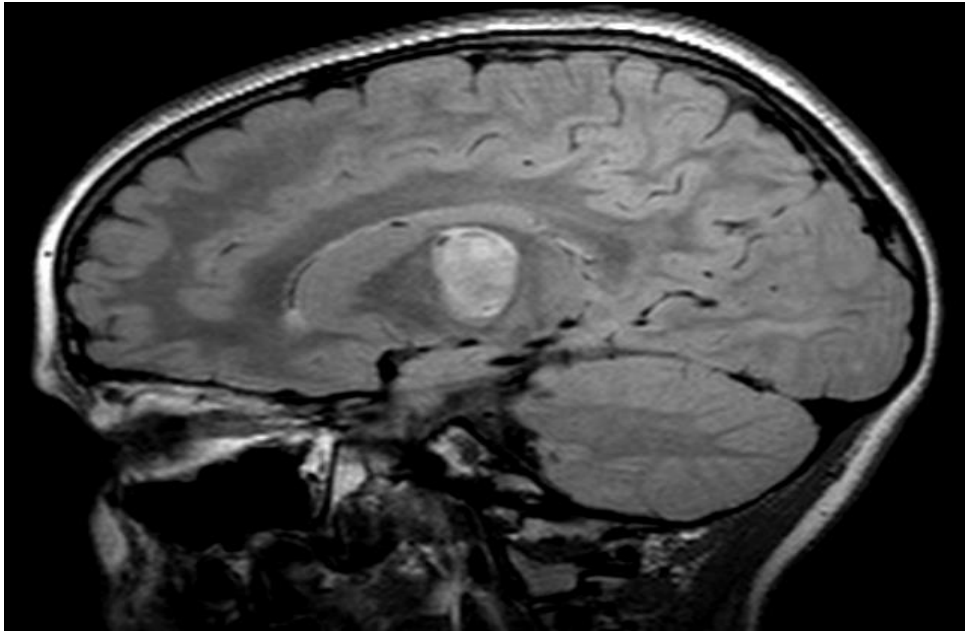

High Field (3 Tesla) FLAIR

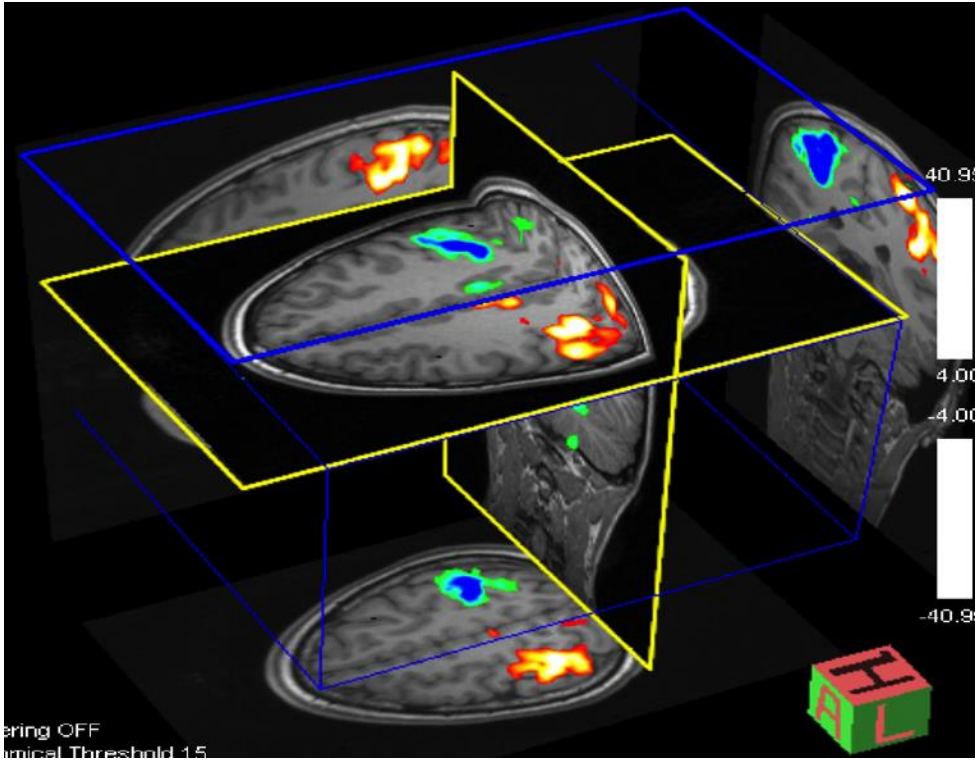

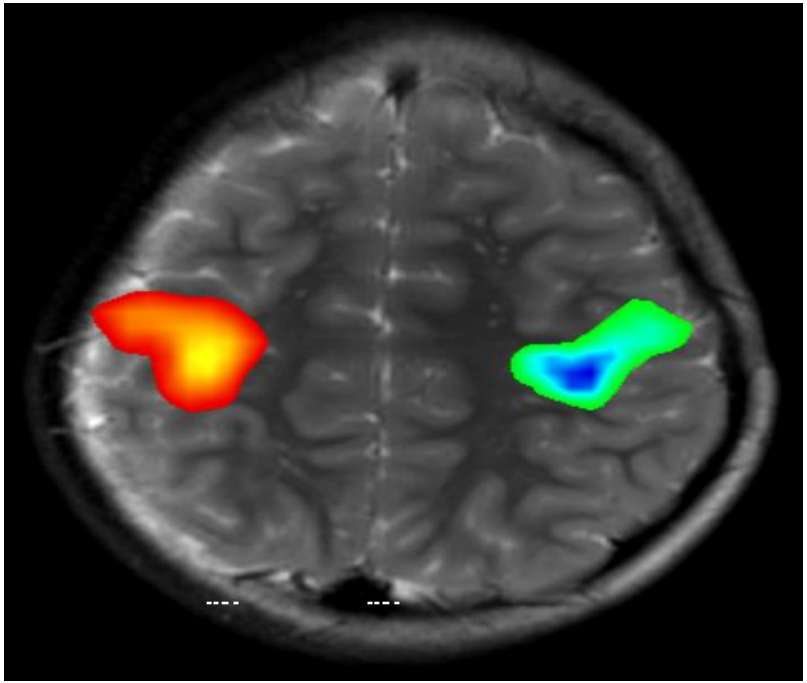

Functional MRI - Bilateral Finger Tapping

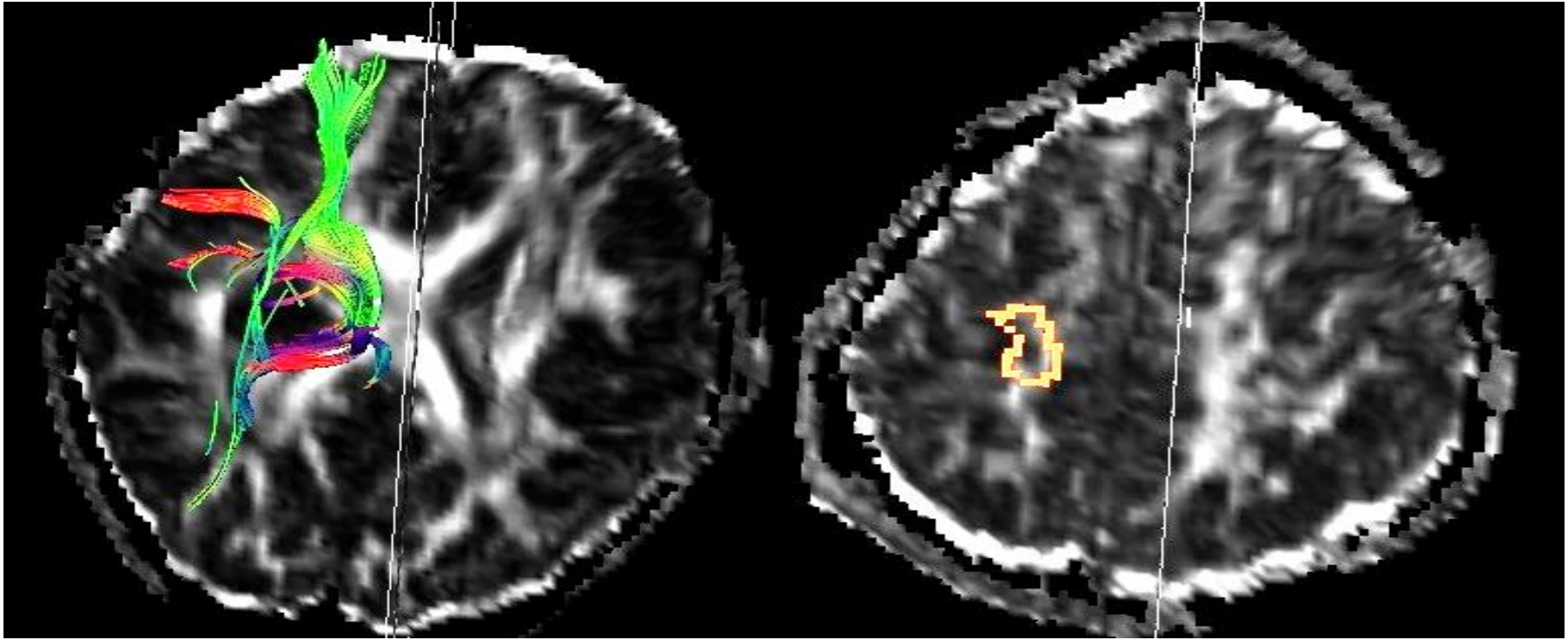

Diffusion Tensor Imaging

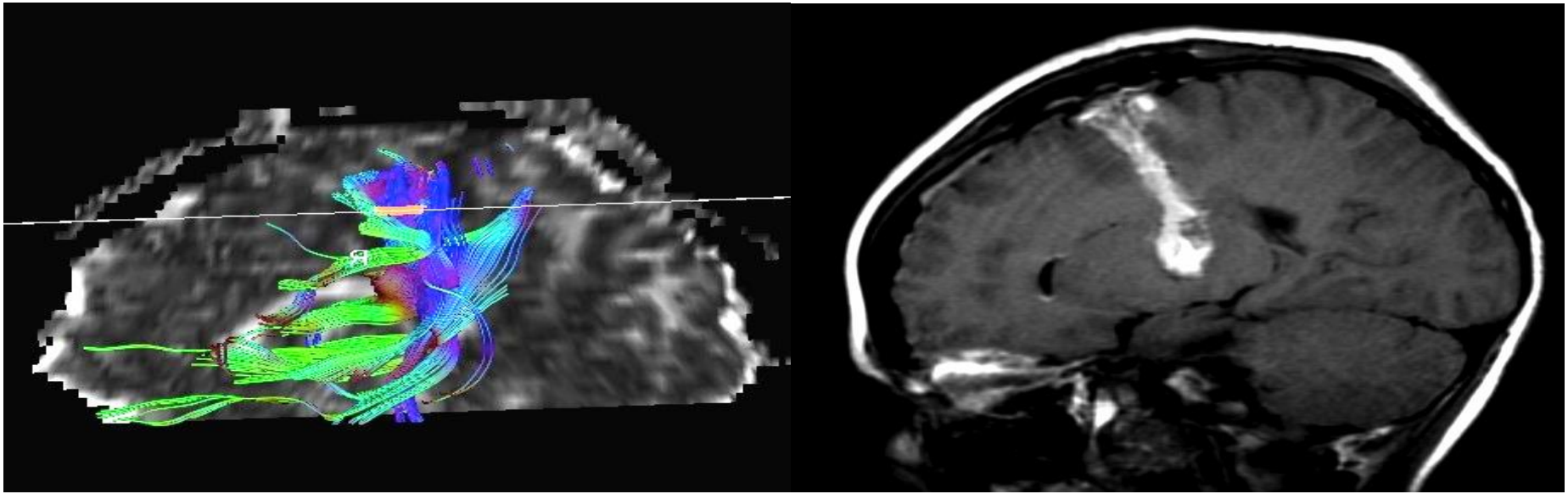

DTI and Post-Surgical Tract

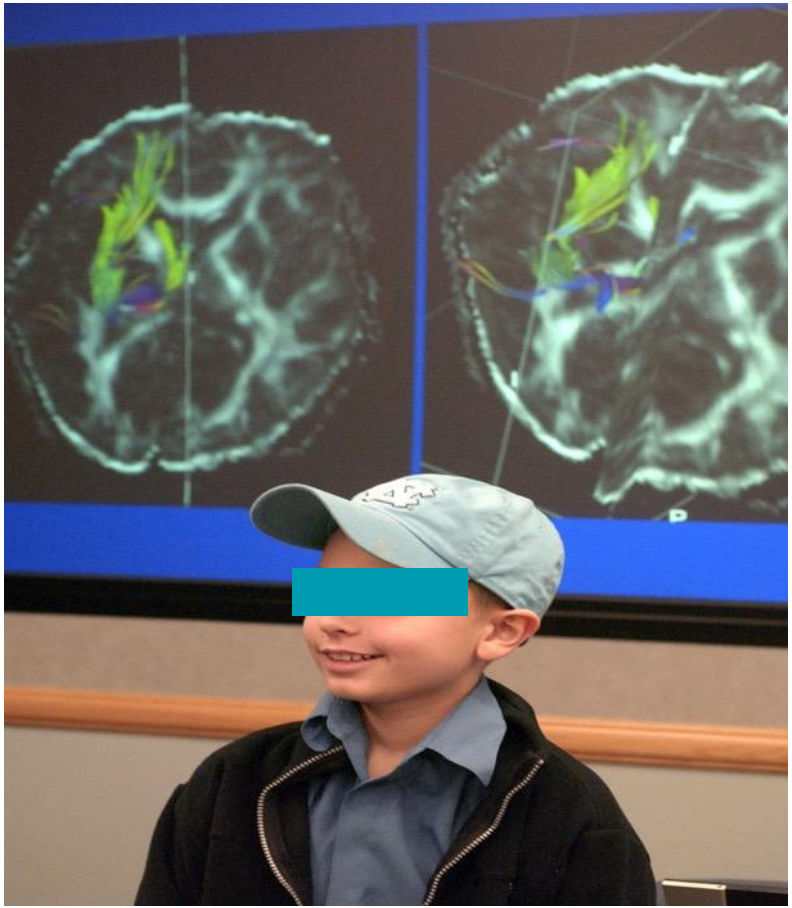

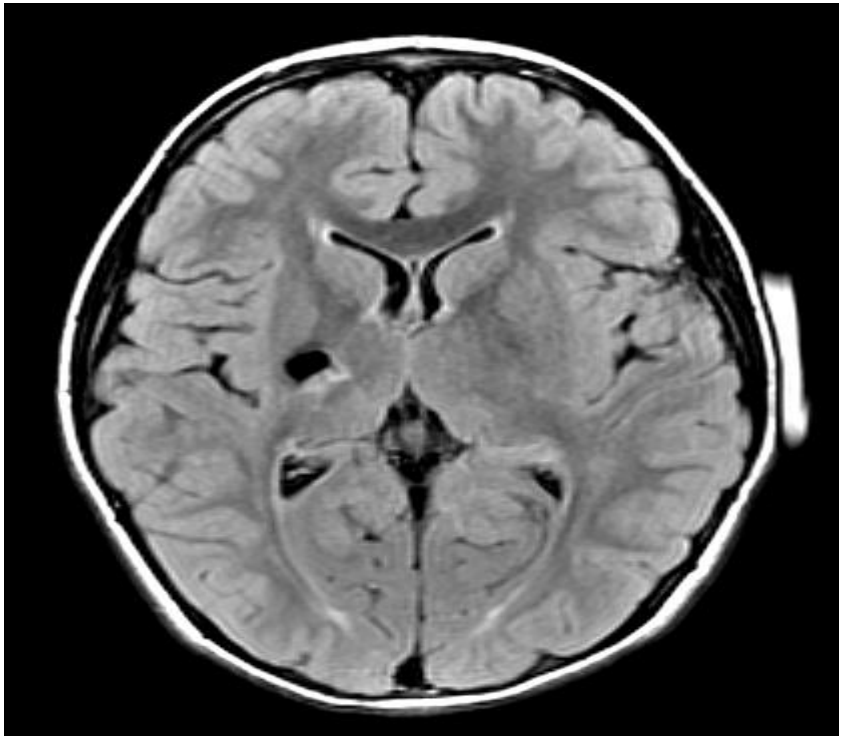

Follow-up

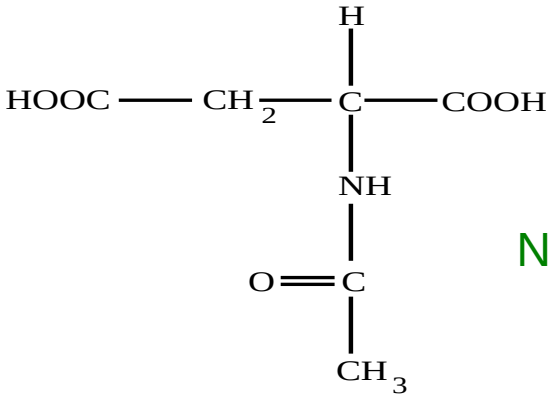

N-acetyl aspartate

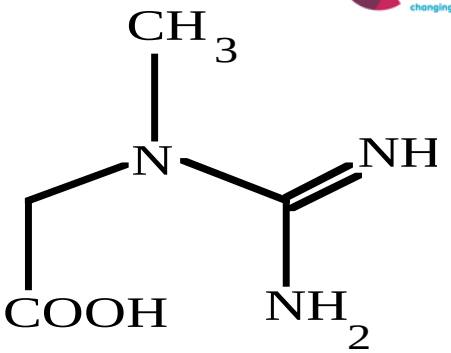

Creatine

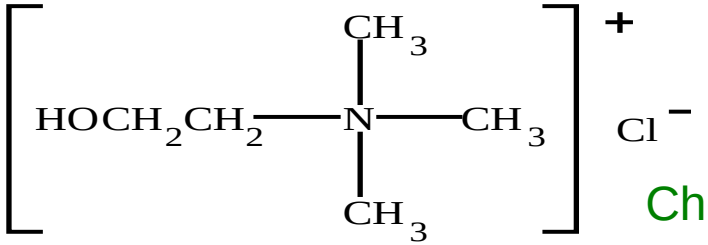

Choline

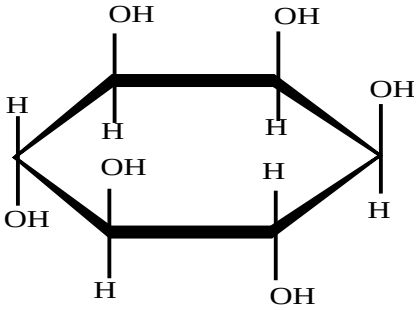

Myo-inositol

Key Metabolites for Brain Magnetic Resonance Spectroscopy

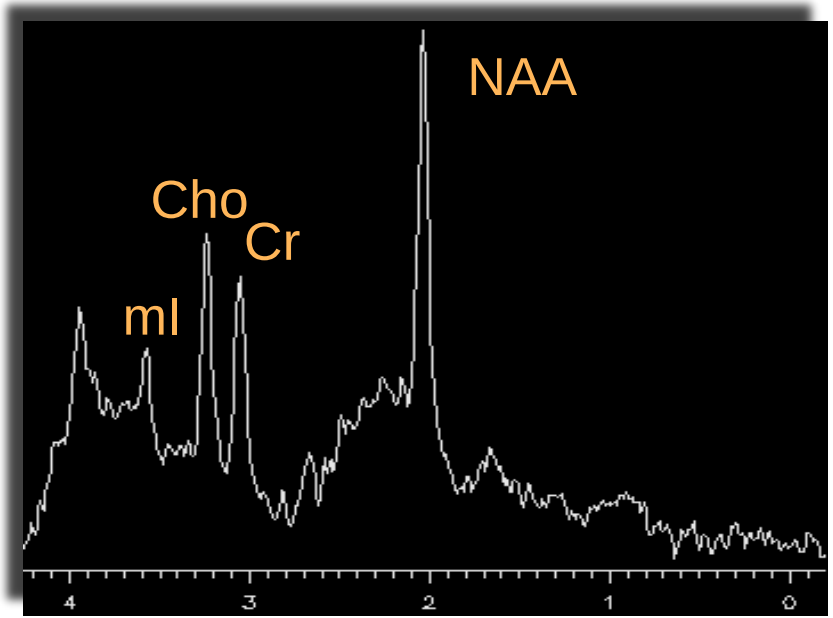

Healthy White Matter

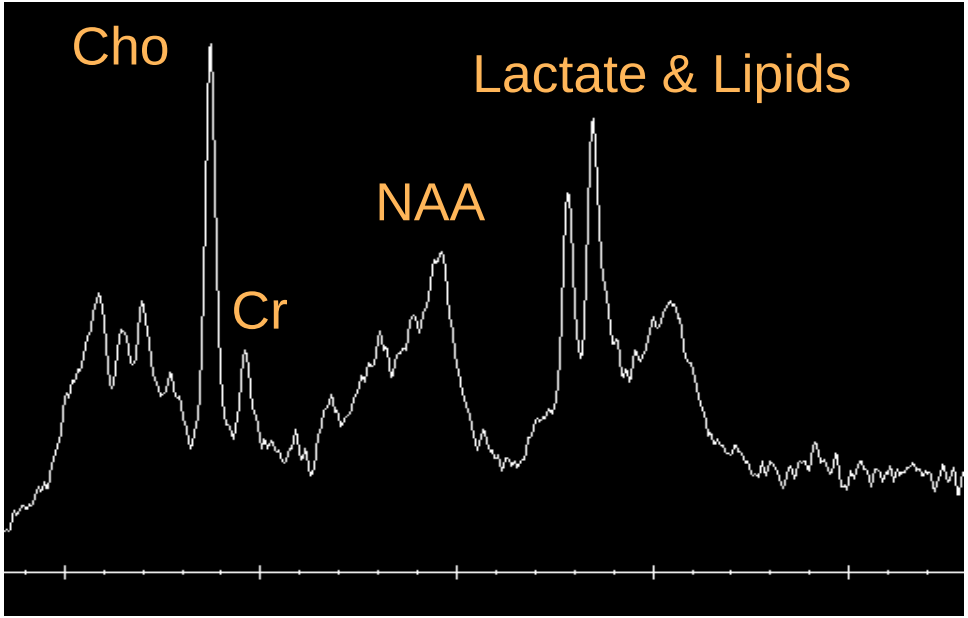

Pilocytic Astrocytoma

Short Echo Comparative Spectroscopy

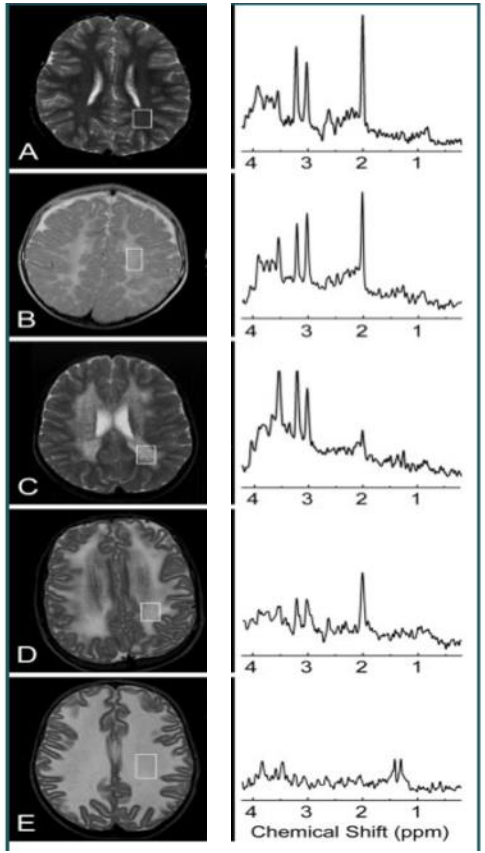

A, Healthy, 5 yr

B, Hypomyelination, 2 y

C, Demyelination, 6 y

D, Myelin Vacuolization, 11 y

E, Cystic Degeneration, 3 y

Radiology, 2006, 241, 510-517

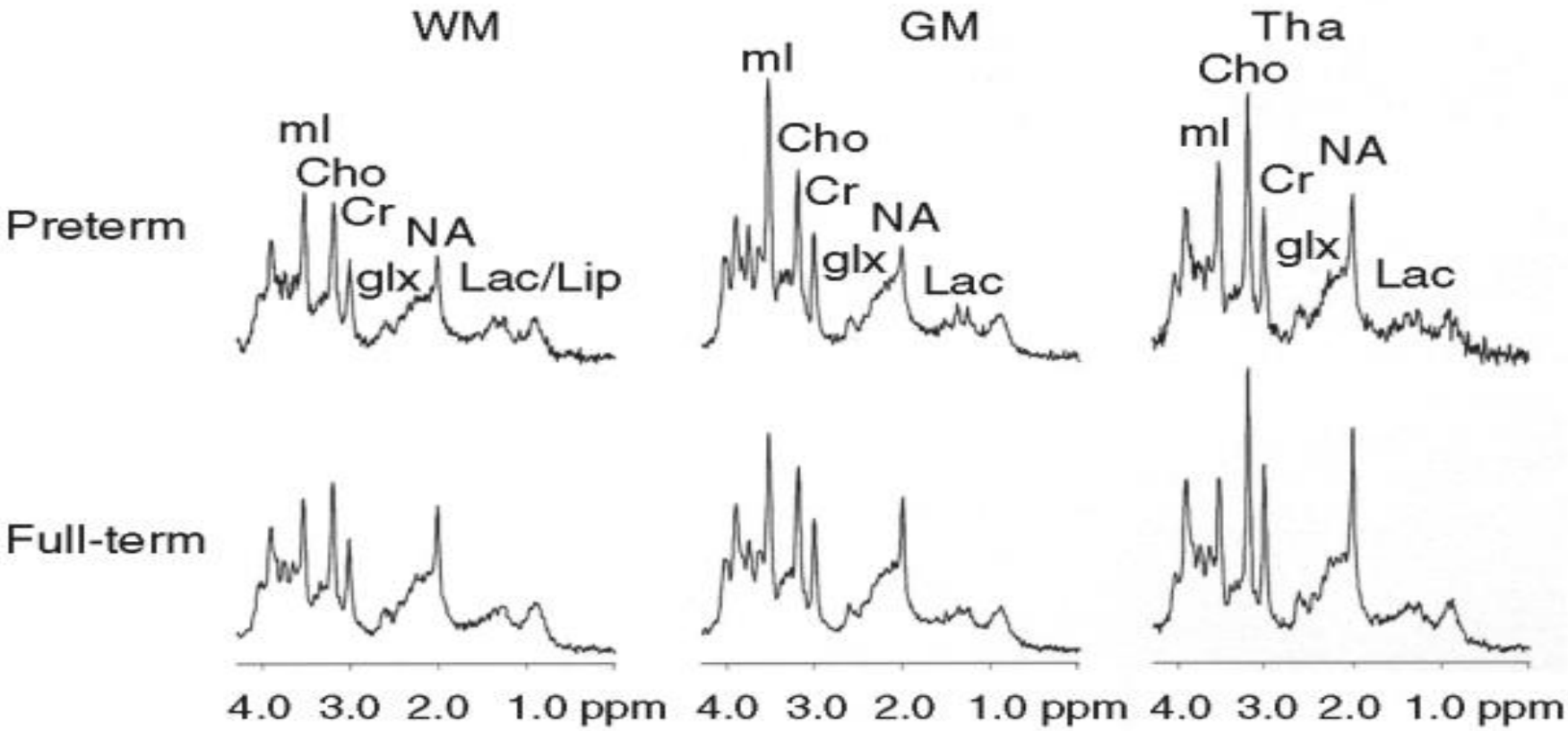
WM
GM
Tha
Preterm
Full-term
mI
Cho
Cr
NA
glx
Lac/Lip
Lac
4.0 3.0 2.0 1.0 ppm

Prospective Research

- Cohort enrolled in epidemiological study
  - Epidemiologists partner with imaging group
- Advanced, quantitative MRI techniques in protocol
- Image processing with epidemiology style statistical support
  - Radiology imaging studies often compare disease group with healthy controls, limited confounders

Cincinnati Lead Study (CLS)

- Do low to moderate blood lead levels alter brain structure, organization or function?

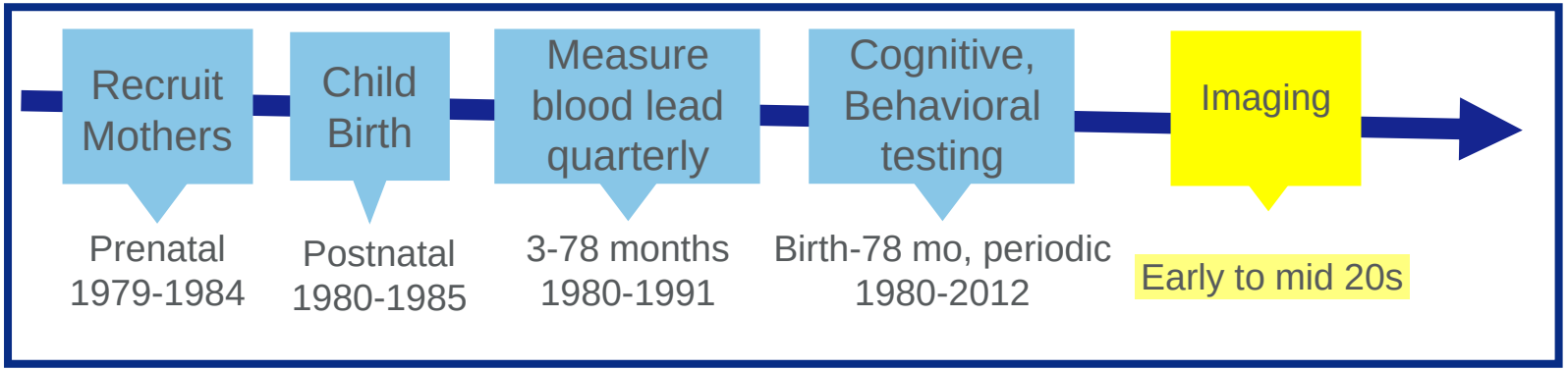

Volume Loss

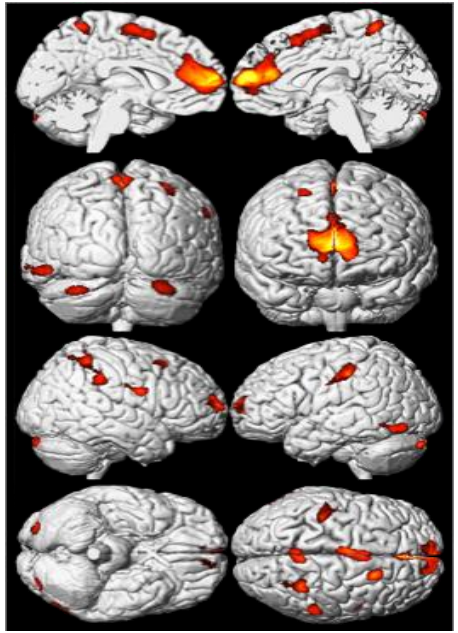

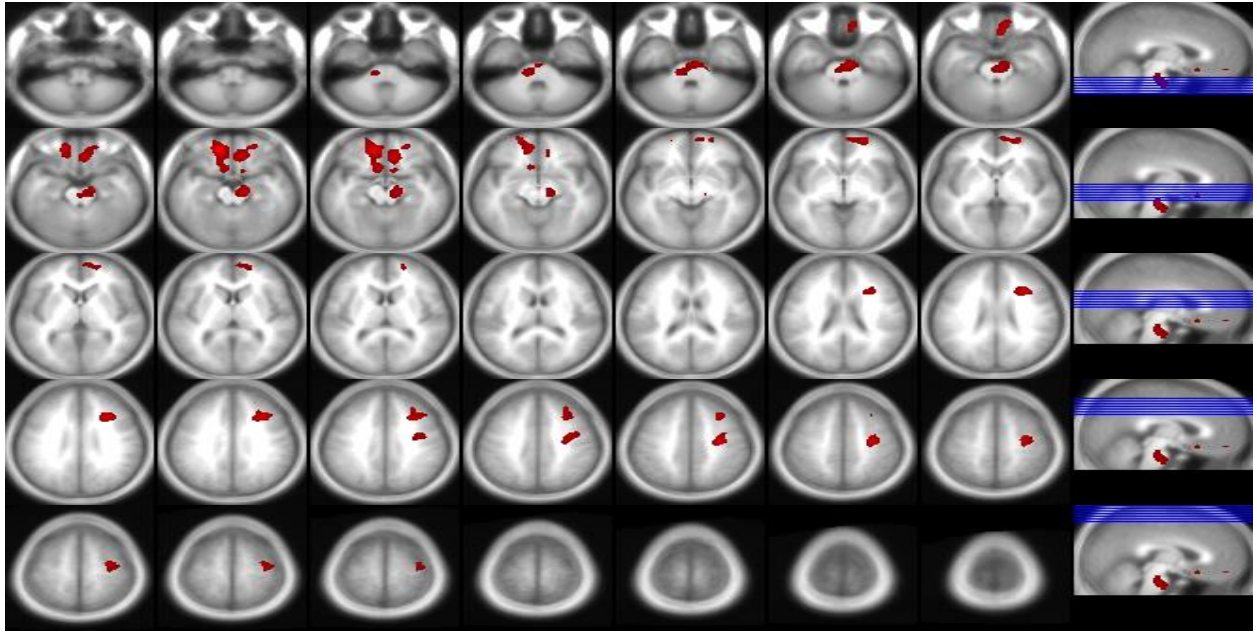

N = 157; *Left, Gray Matter Loss** Adjusted for age at imaging and birth weight (gray matter); *Right*, *White Matter Loss* Adjusted for maternal IQ (white matter).

PLoS Medicine 2008, 5(5), e112*

fMRI Verb Generation

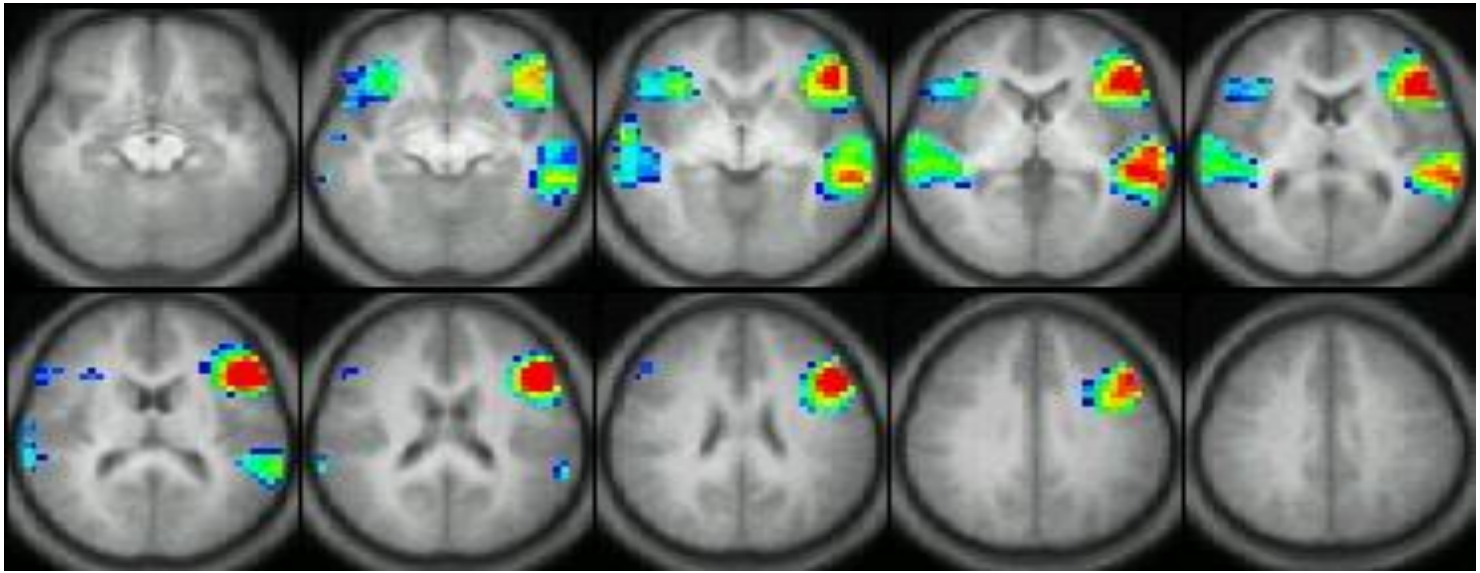

N= 42, Composite Z-map for brain activation associated with verb generation

Pediatrics 2006, *118*, 971-977

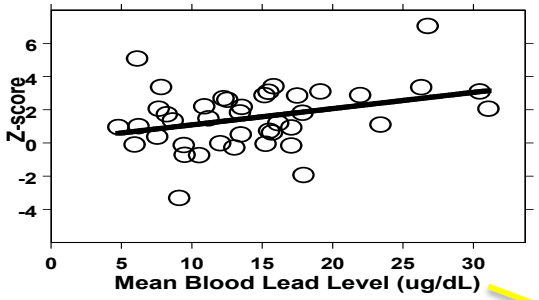

N= 42, Multivariate linear regression of brain activation associated with mean childhood blood lead levels adjusted for birth weight and marijuana use

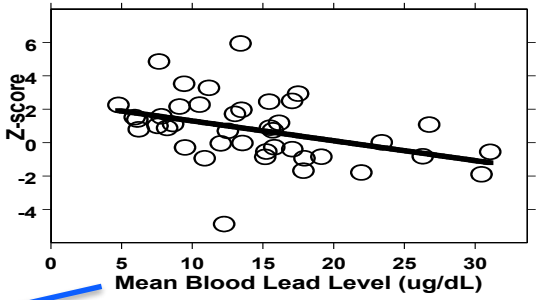

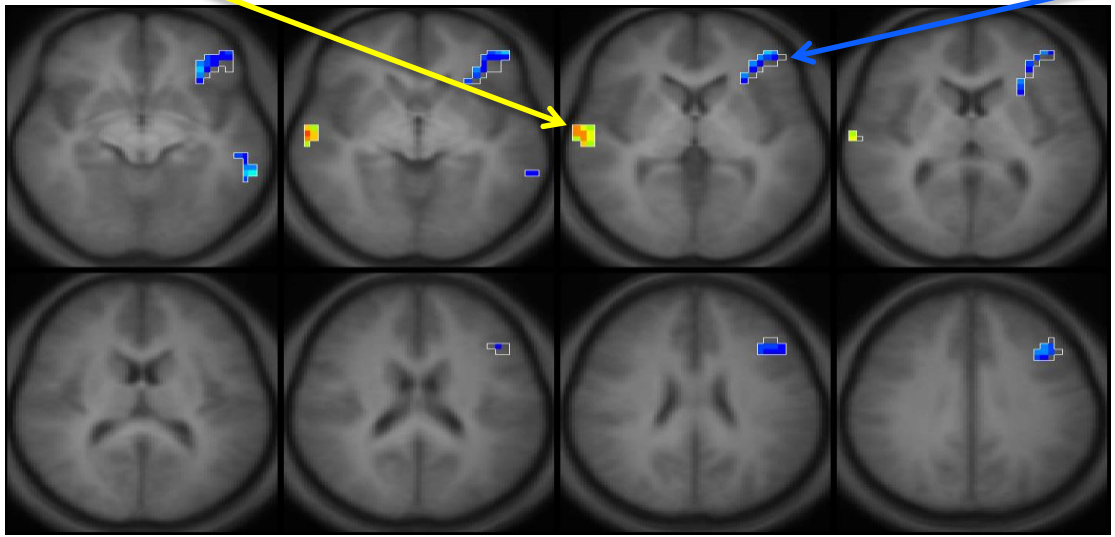

Diffusion Tensor Imaging

Fractional Anisotropy *(tight packing)*

Mean Diffusivity *(intracellular)*

Axial Diffusivity *(axonal integrity)*

Radial Diffusivity *(1/myelination)*

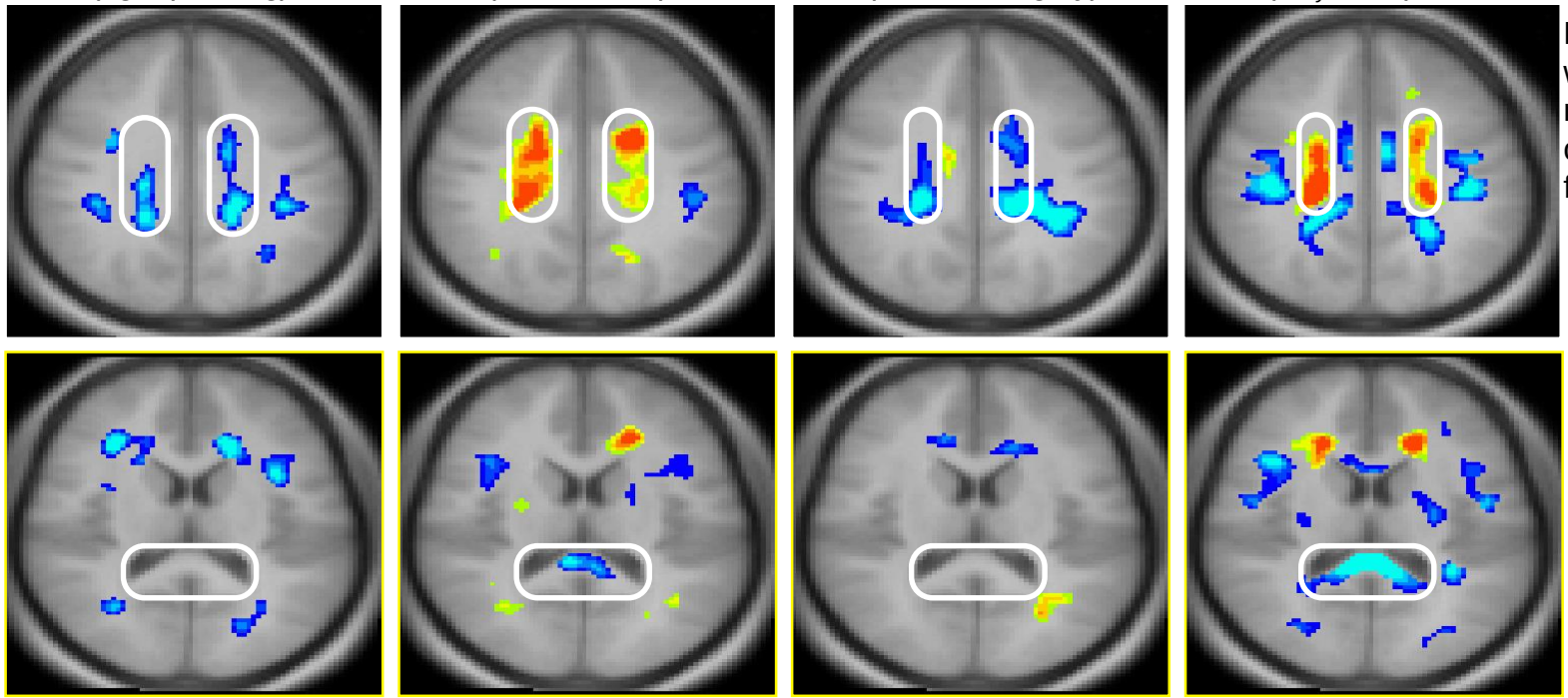

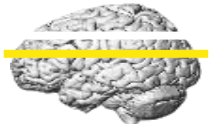

Lead is associated with axonal *and* myelin dysfunction of long association fibers

Z statistic

Apparent *increase* in myelination in crossing fibers of splenium of the corpus callosum

Neurotoxicology 2009, *30*, 867-875

Acknowledgements

National Institute of Environmental Health Sciences grant awards supporting imaging and environmental health outcomes:

Lead (CLS): P01 ES011261, P30 ES006096, R01 ES015559

Air pollution (CCAAPS): R01 ES019890

Common toxicants (HOME): R01 ES027224, R01 ES028277

Manganese (CARES): R01 ES026053